

Chapter II. Stages of Embryonic Development

II.1 Second Week of Embryonic Development

II.2.1. Implantation

Implantation is the process by which the embryo establishes a close relationship with the maternal organism.

II.2.2. Chronology of Implantation

Implantation is categorized chronologically into early and late stages:

- ✓ **Early Implantation:** Occurs immediately after blastocyst hatching (12–48 hours). The trophoblast does not expand, and the blastocyst implants via its embryonic pole at the base of an endometrial crypt (rodents) or within the endometrium (primates).
- ✓ **Late Implantation:** The embryo nourishes itself through imbibition and only establishes implantation after several days or weeks (e.g., Mare: 56 days; Cow: 35 days; Ewe: 15 days; Bitch: 15 days; Sow: 10 days).

II.2.3. Site of Implantation

The site of implantation within the uterus varies by species and is classified into three types:

- ✓ **Central (or Superficial) Type:** The blastocyst remains free in the uterine lumen for a relatively long period, growing until it contacts the entire perimeter of the cavity before attaching to the endometrium; examples: Carnivores, ungulates, and rabbits.
- ✓ **Eccentric Type:** The blastocyst wedges itself between the highly developed folds of the uterine mucosa and grows. The edges of the folds harboring it eventually fuse, forming a closed chamber isolated from the uterine lumen ; examples: Mice and rats.
- ✓ **Interstitial Type:** The blastocyst attaches early to the endometrium and embeds itself by eroding the surface. The mucosa then closes over it, and the trophoblast undergoes significant modification during growth ; examples: Primates and guinea pigs.

In **polytocous species** (where multiple blastocysts are present and result in several offspring per litter), such as carnivores, rabbits, and rodents, uterine contractions occur from the beginning of the pre-implantation stage. These contractions are responsible for distributing the blastocysts along the entire length of the uterus with regular spacing. The uterine contractions ensure the embryos are evenly spread throughout the uterine horn.

II.2.4. Stages and Mechanisms of Implantation

After the loss of the **zona pellucida** (hatching), the blastocyst positions itself within the uterus. Its orientation is not random but is a constant characteristic of the species. The blastocyst orients itself so that the **embryonic pole** (embryonic disc) faces the uterine epithelium (Figure 2).

Then there is the apposition or simple contact between the trophoectoderm epithelium and the endometrium. Adhesion between the two epithelial tissues occurs when the microvilli on the surface of the outermost trophoblastic cells interlock with those of the uterine epithelial cells, forming an interpenetrating system.

Junctional complexes are formed, ensuring stronger adhesion. This phase constitutes the final stage of implantation in species with epithelio chorial placentation (equines, bovines, and porcines). During invasion, the chorion emits its villi and becomes firmly anchored in the uterine wall. The extent of the damage caused to the uterus varies depending on the type of placentation.

The trophoblast may completely erode the uterine epithelium, cross the basal membrane, and penetrate into the stroma until it reaches: the wall of blood vessels (species with endothelio chorial placentation, e.g., carnivores), or the blood vessels themselves (species with hemo chorial placentation, e.g., rodents).

For implantation to occur in the uterus, there must be synchronization between the age of the embryo and the stage of uterine development in the cycle.

This receptivity of the endometrium, called the “implantation window,” results from the secretion of adhesion proteins by the endometrium, whose synthesis is stimulated by progesterone. Any modification of the uterine environment can prevent implantation; therefore, the uterus may play an inhibitory role in implantation.

II.2.4. Main abnormalities of implantation

- ✓ **Ectopic implantation:** The egg at the blastocyst stage may stop at any point during its migration. It may then degenerate or implant, resulting in an extra-uterine pregnancy (most often in the ampulla, rarely in the interstitial segment). Migration abnormalities may also, though more rarely, lead to other types of ectopic pregnancies such as ovarian or abdominal pregnancies.
- ✓ **Cervical implantation or low implantation:** This occurs in the lower segment of the uterus, leading to the formation of placenta previa, which can cause severe hemorrhage at the end of pregnancy or at the time of birth (in primates).
- ✓ **Implantation outside the uterus:** This leads to an ectopic pregnancy and may cause rupture of the fallopian tube, resulting in internal hemorrhage.

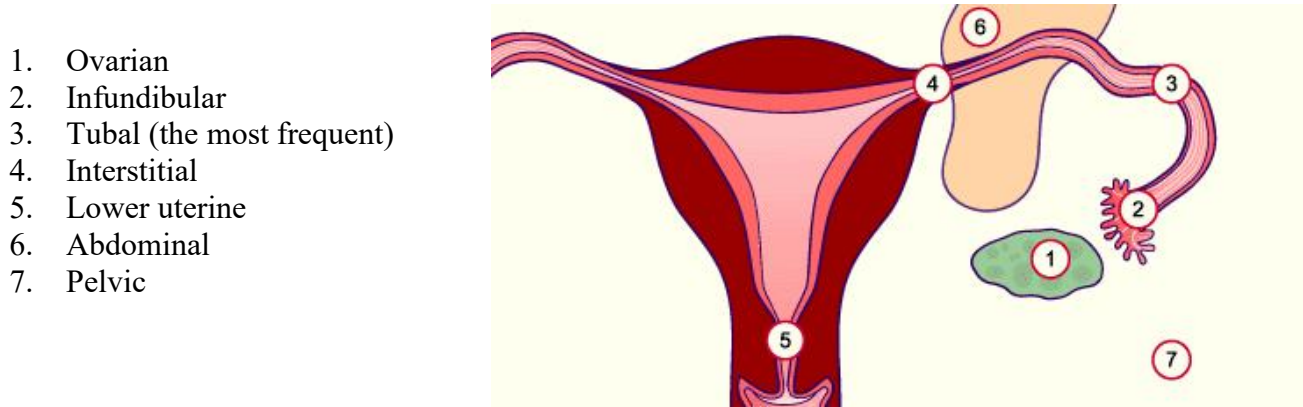


Figure 1:Main abnormalities of implantation

Pre-gastrulation

This is an intermediate stage between cleavage and gastrulation, typical of Amniotes (birds and mammals) that develop embryonic annexes. It results in the formation of two embryonic layers: the **ectoblast** and the **endoblast**.

In humans, this occurs from the 7th to the 14th day. As the **trophoblast** evolves to facilitate **nidation** (implantation), the rest of the blastocyst inside the cytotrophoblast undergoes four major changes:

- ✓ Transformation of the inner cell mass (embryonic knob) into an **embryonic disc**.
- ✓ Formation of the **amniotic cavity**.
- ✓ Formation of the **extra-embryonic mesenchyme** and the **primary yolk sac** (lécithocèle).
- ✓ Evolution of the extra-embryonic mesenchyme (appearance of the **extra-embryonic coelom**) and the establishment of the **secondary yolk sac**.

Inner Cell Mass (Embryonic Knob)

It differentiates into a didermic germ made of:

- ✓ **Ectoblast (Epiblast):** An external layer composed of large cells.
- ✓ **Endoblast (Hypoblast):** An internal layer composed of small cells.

Trophoblast

As the blastocyst sinks into the endometrium, the trophoblast differentiates into two layers:

- ✓ **Cytotrophoblast :** The inner layer of clear, mononucleated cells where many mitoses (cell divisions) occur.

- ✓ **Syncytiotrophoblast:** The outer layer of multinucleated cells without distinct boundaries (a syncytium). It secretes enzymes that erode the uterine epithelium and connective tissue to allow implantation.

Development of Annexes

✓ **Formation of the Amnion**

Vacuoles appear between the ectoblast and the trophoblast. These fuse to form the **amniotic cavity**.

- ✓ **Roof/Sides:** Formed by **amnioblasts** (differentiated cytotrophoblast cells).
- ✓ **Floor:** Formed by the **ectoblast**.

Formation of the Mesenchyme

Around the 10th day, cytotrophoblast cells lining the blastocyst cavity differentiate into star-shaped **mesenchymal cells**. The first cells to form the innermost lining create **Heuser's membrane**. This mesenchyme then proliferates and spreads between the amnioblasts and the cytotrophoblast.

Formation of the Yolk Sac (Lécithocèle)

- ✓ **Primary Yolk Sac:** The original blastocyst cavity, now bounded by the endoblast (top) and Heuser's membrane (bottom).
- ✓ **Secondary Yolk Sac:** The endoblast proliferates toward the anti-embryonic pole, pushing Heuser's membrane aside. This "pinches off" the primary sac, leaving a large cavity lined by endoblast (the secondary yolk sac) and a small remnant of the primary sac.

Formation of the Extraembryonic Coelom and Mesenchymal Condensation

The mesenchymal cells condense into layers applied against the **secondary yolk sac** and the **amnioblasts** on one side, and the **cytotrophoblast** on the other. This process releases a large cavity known as the **extraembryonic coelom** (or chorionic cavity), which is filled with coelomic fluid.

The layers resulting from this mesenchymal condensation are:

- ✓ **Chorionic plate (Lame choriale):** The mesenchyme pressed against the inner surface of the cytotrophoblast.
- ✓ **Connecting stalk (Pédicule de fixation):** The mesenchyme located between the roof of the amniotic cavity and the cytotrophoblast; this will eventually become the umbilical cord.
- ✓ **Extraembryonic splanchnic mesoderm (Splanchnopleure extra-embryonnaire):** The mesenchyme pressed against the outer surface of the secondary yolk sac wall.
- ✓ **Extraembryonic somatic mesoderm (Somatopleure extra-embryonnaire):** The mesenchyme pressed against the sides of the amniotic cavity.