



Cours de Pathologie de la Reproduction
destinés aux étudiants de 4^{ème} ADV

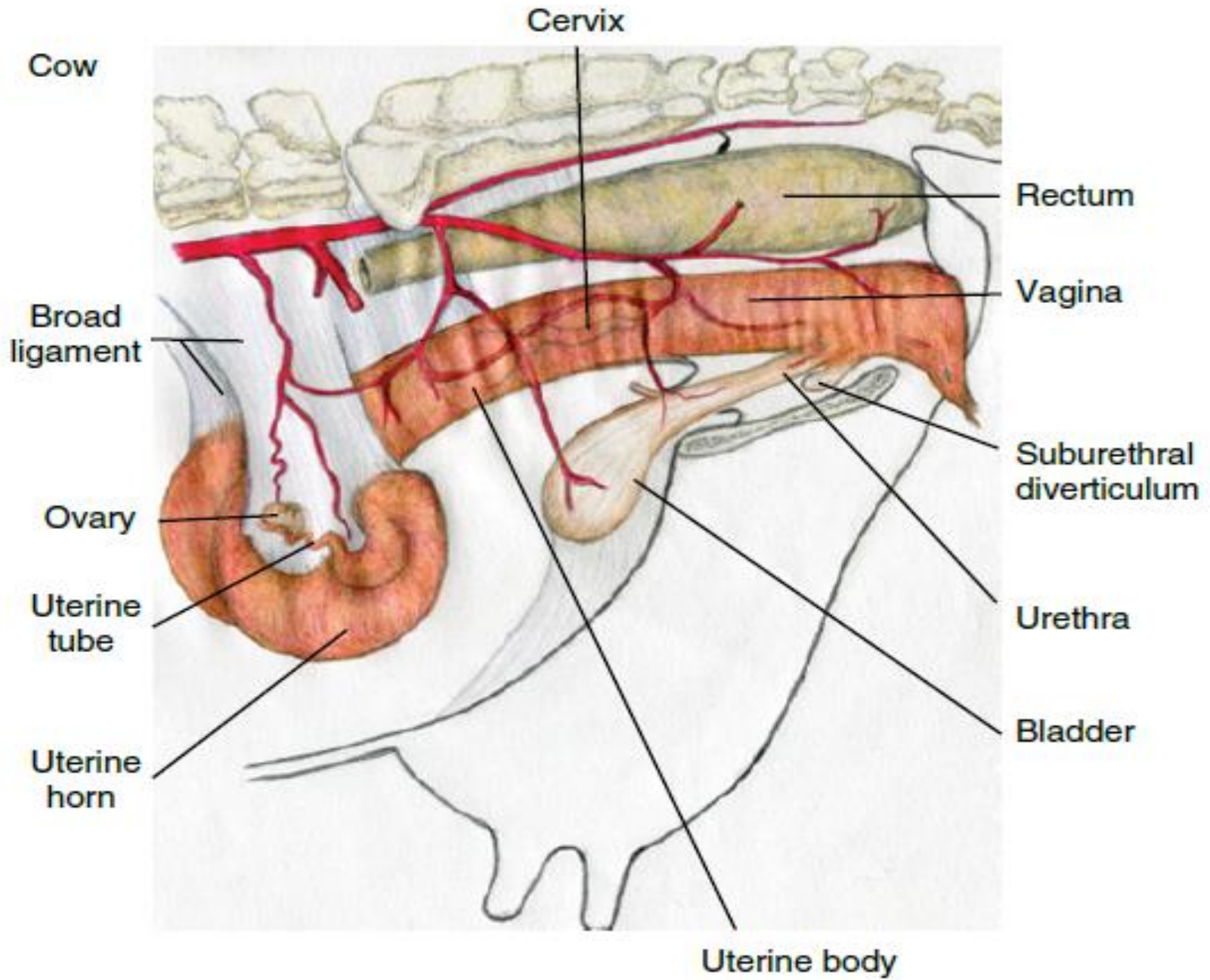


RAPPELS ANATOMIQUES DU BASSIN FEMELLE: ILLUSTRATIONS

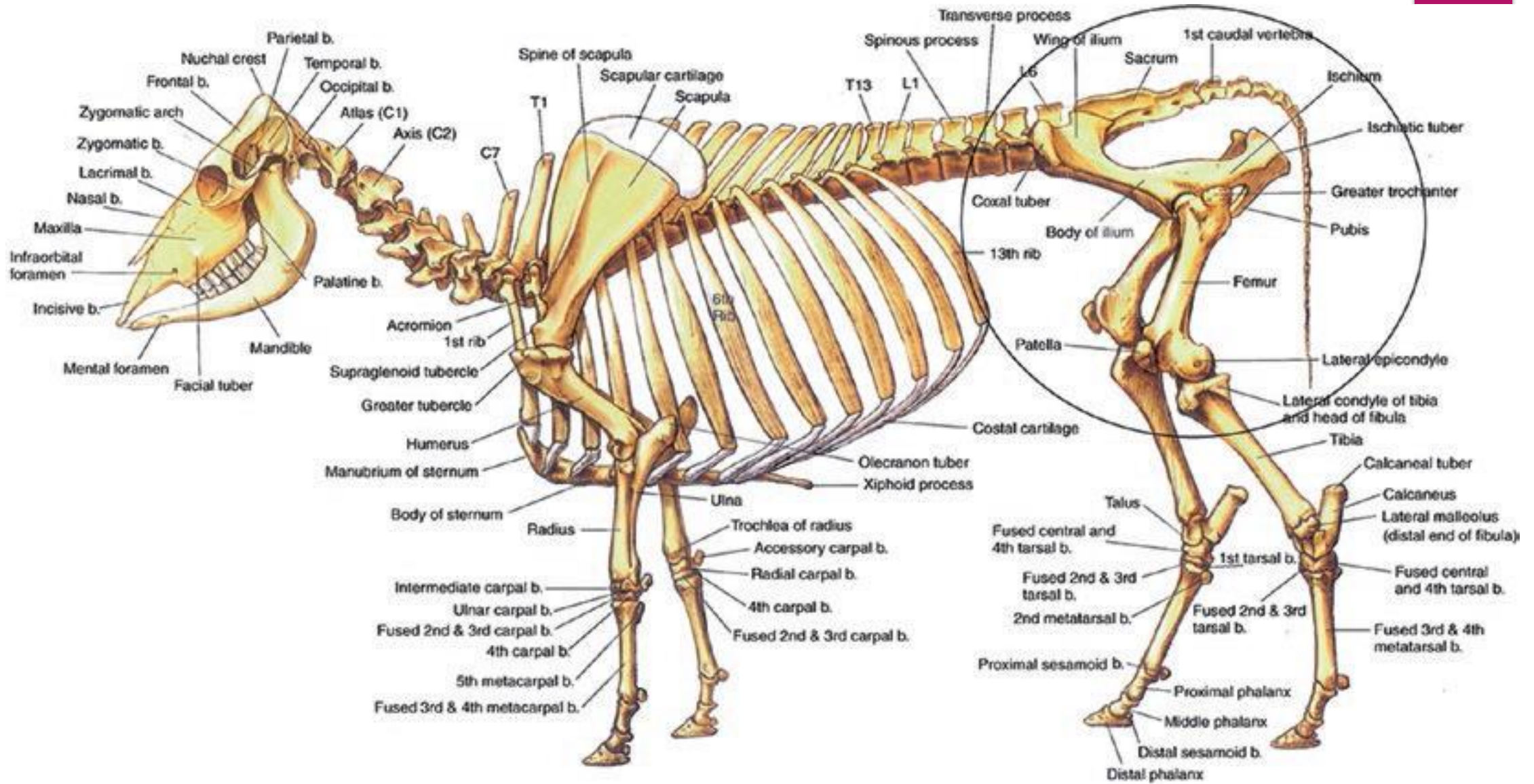
Par:

Prof. Sana HIRECHE

Année universitaire: 2023 – 2024







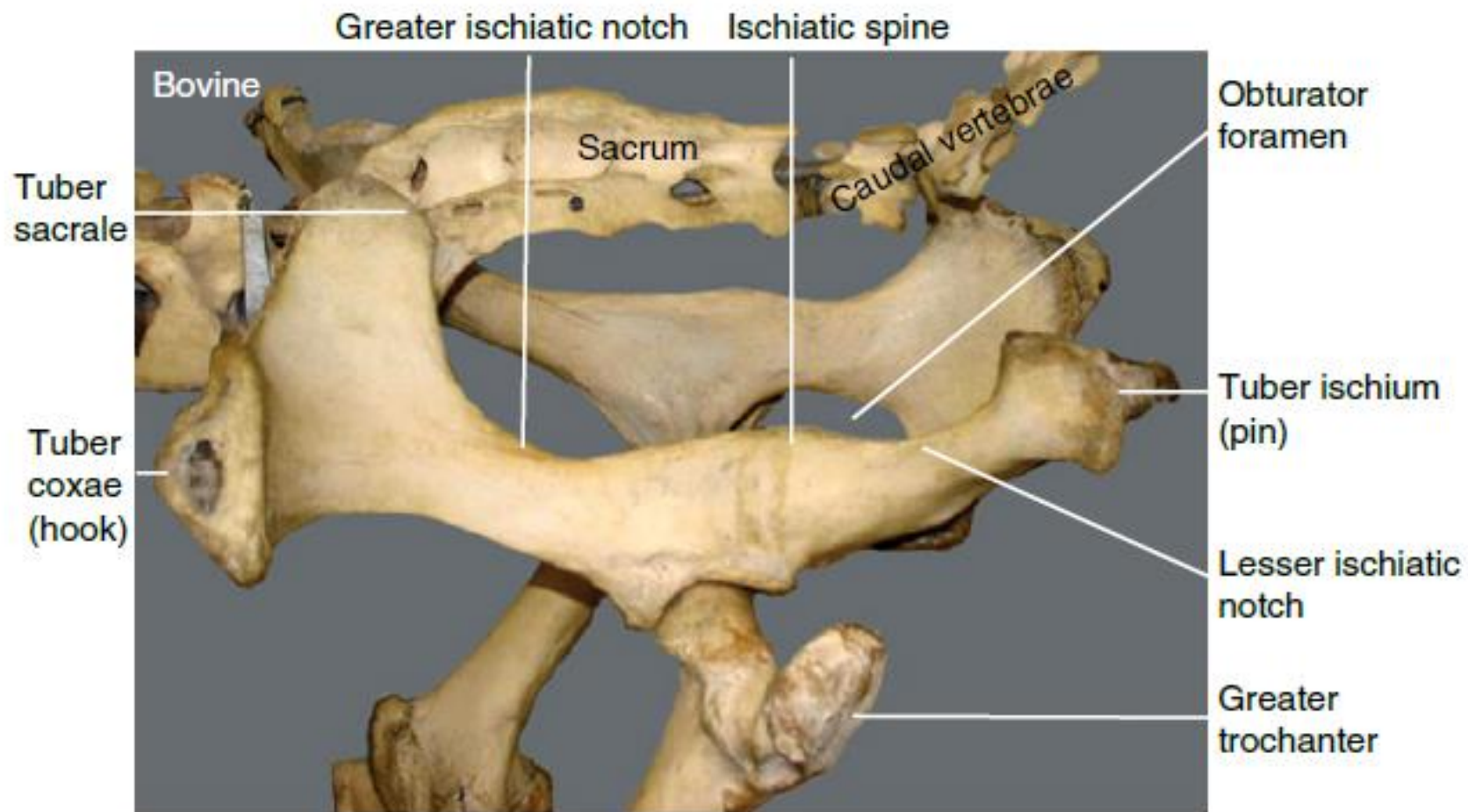
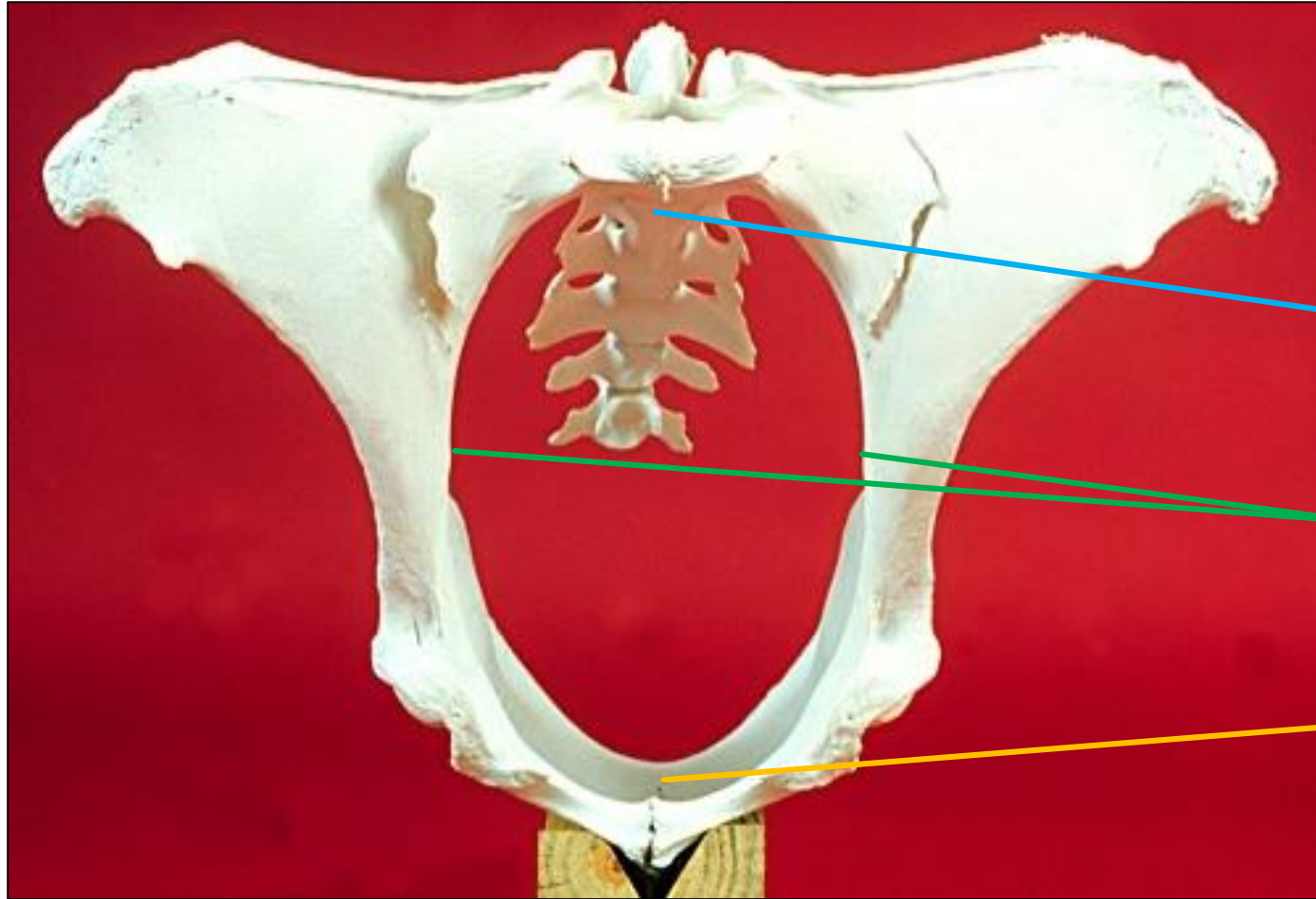


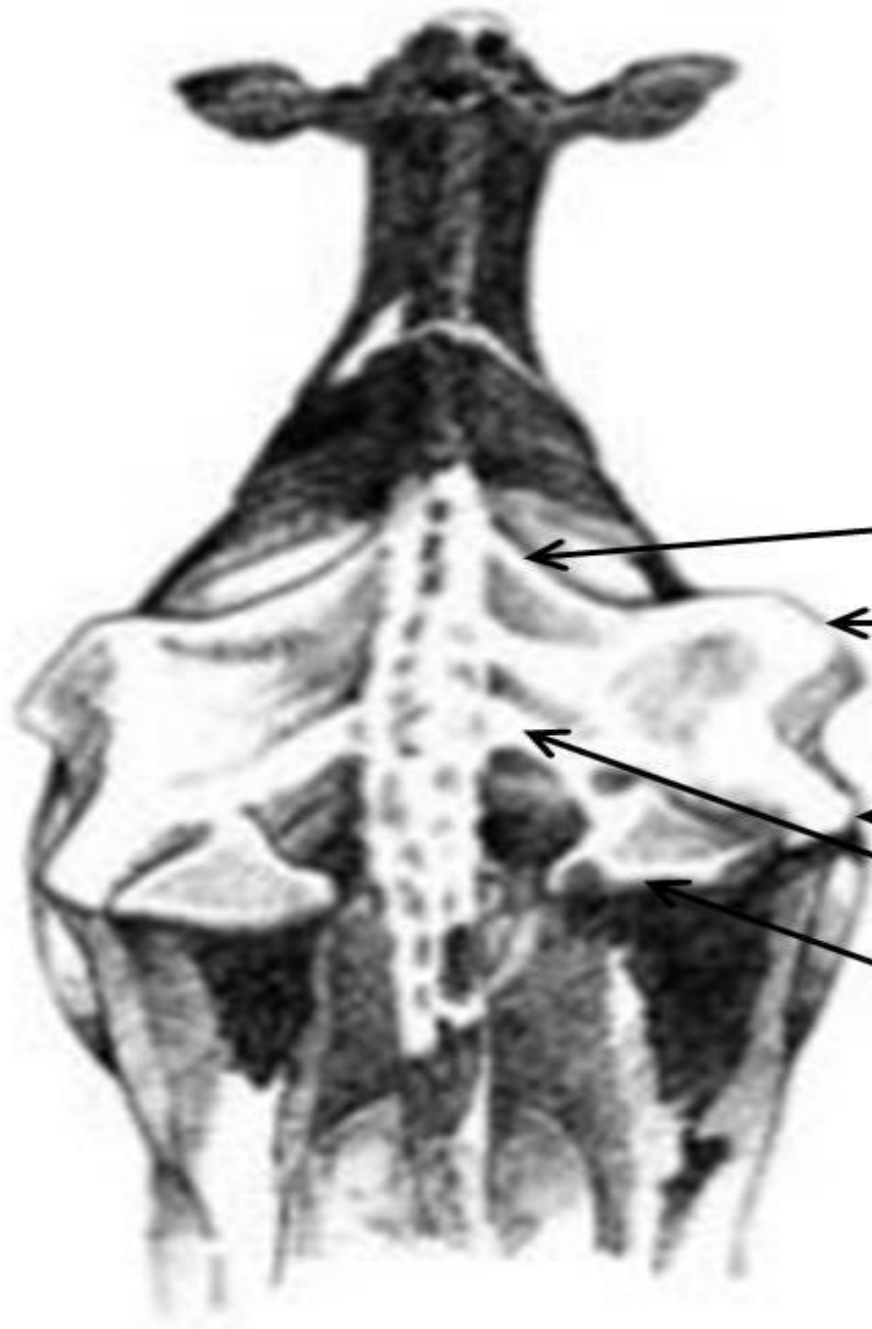Figure 4.1 Bones of the bovine pelvis. Note the vertical and horizontal diameters of the pelvis. They are important measurements used for predicting calving difficulties. Differences in pelvic inlet and outlet exist between the male and female pelvis (Box 4.1).



Plafond du bassin

Parois latérales

Plancher du bassin



Angle de la croupe
(épine iliaque dorso-crâniale)

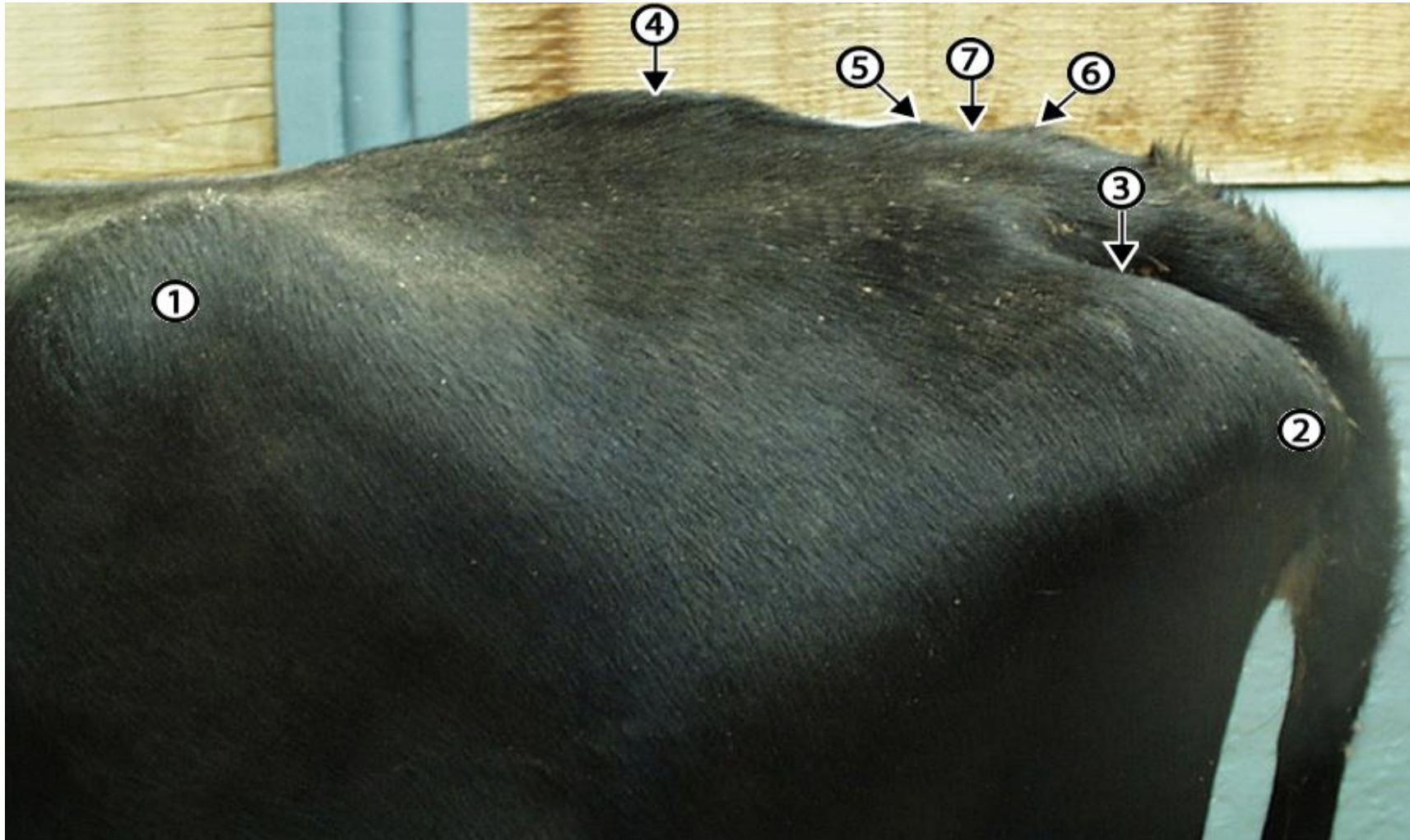
Angle de la hanche
(épine iliaque ventro-crâniale)

Sommet du trochanter

Ligament sacro-sciatique

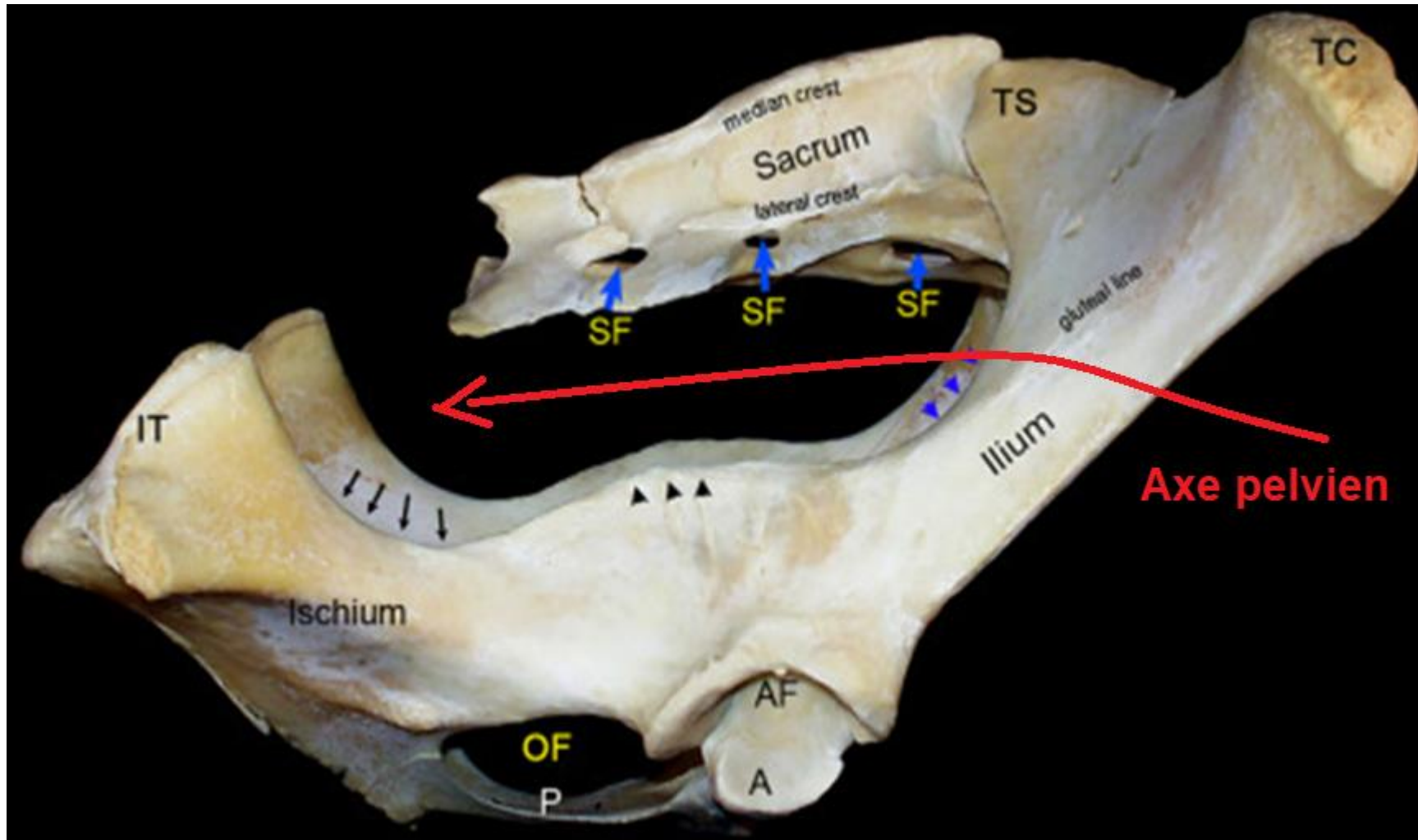
Pointe de la fesse
(tubérosité ischiatique)

Les repères
externes du
bassin



Live cow, palpable pelvic landmarks. 1, coxal tuber (hook bone); 2, ischial tuber (pin bone); 3, caudal edge of sacrosciatic ligament; 4, fused sacral spines 1-3; 5, spine of fifth sacral vertebrae; 6, spine of first caudal vertebrae; 7, sacrocaudal joint (injection point for epidural anesthetics).

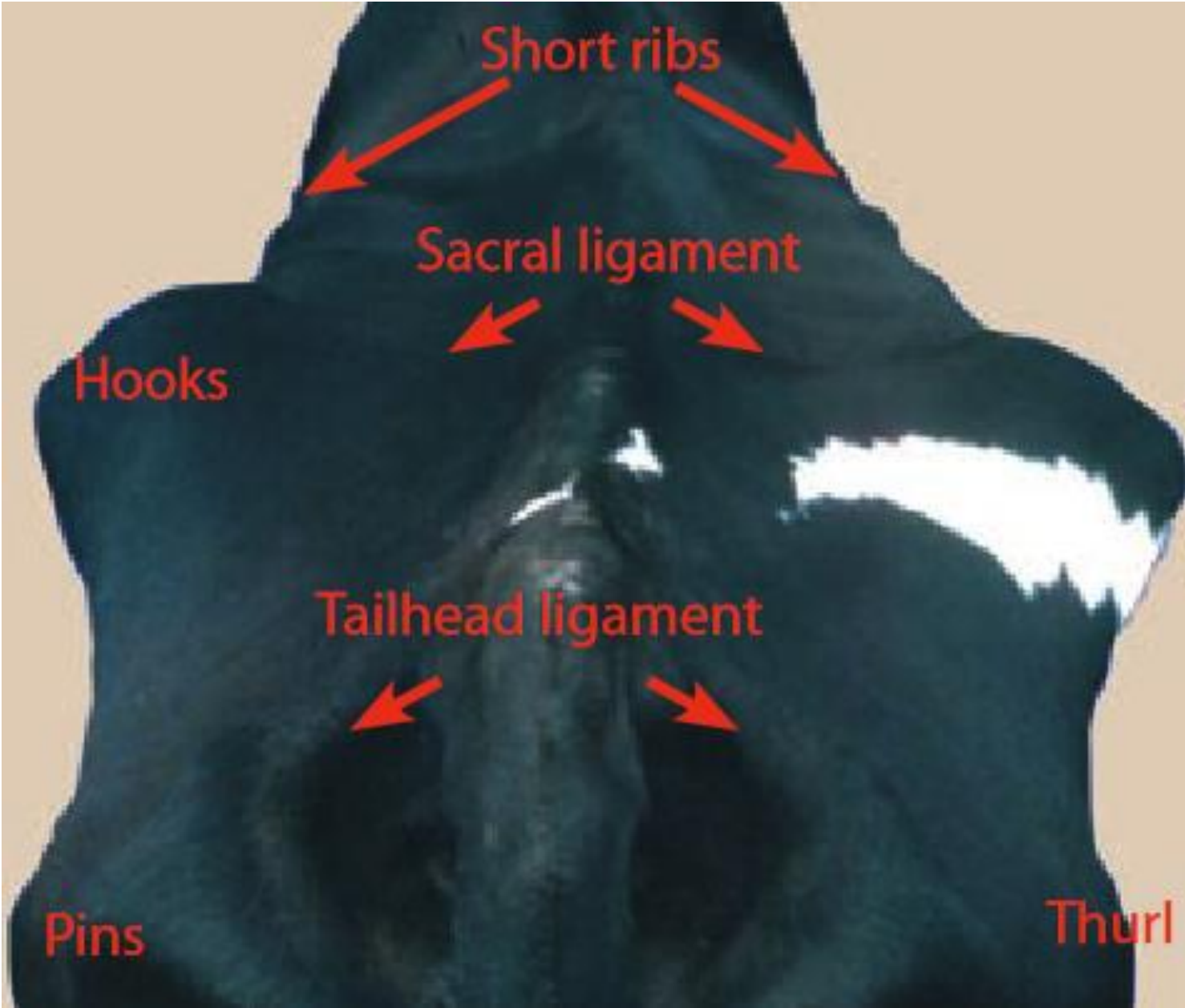
<http://vanat.ahc.umn.edu/ungDissect/Lab05/Img5-18.html>

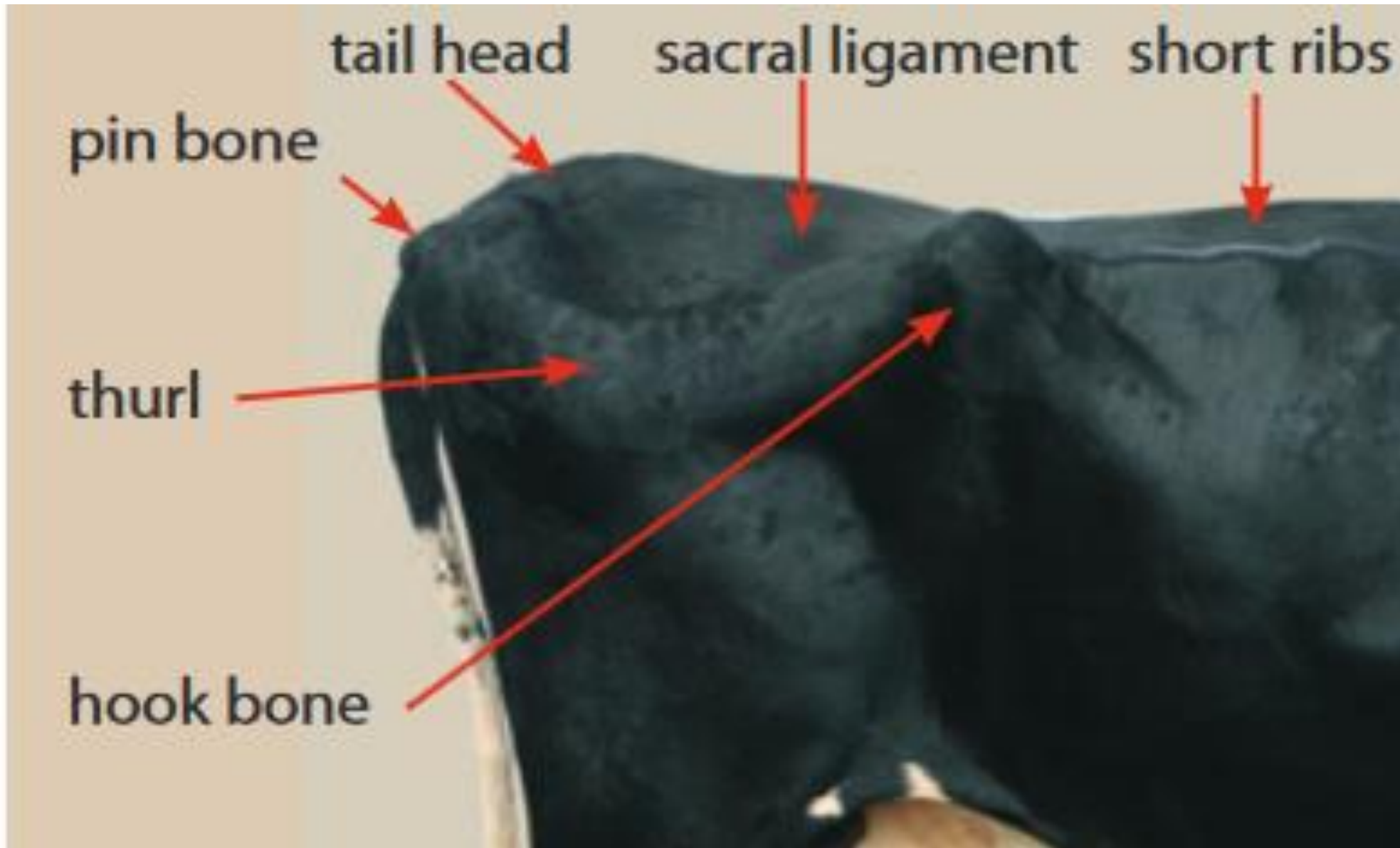


Les mouvements de l'articulation sacro-iliaque participent à l'élargissement du détroit postérieur

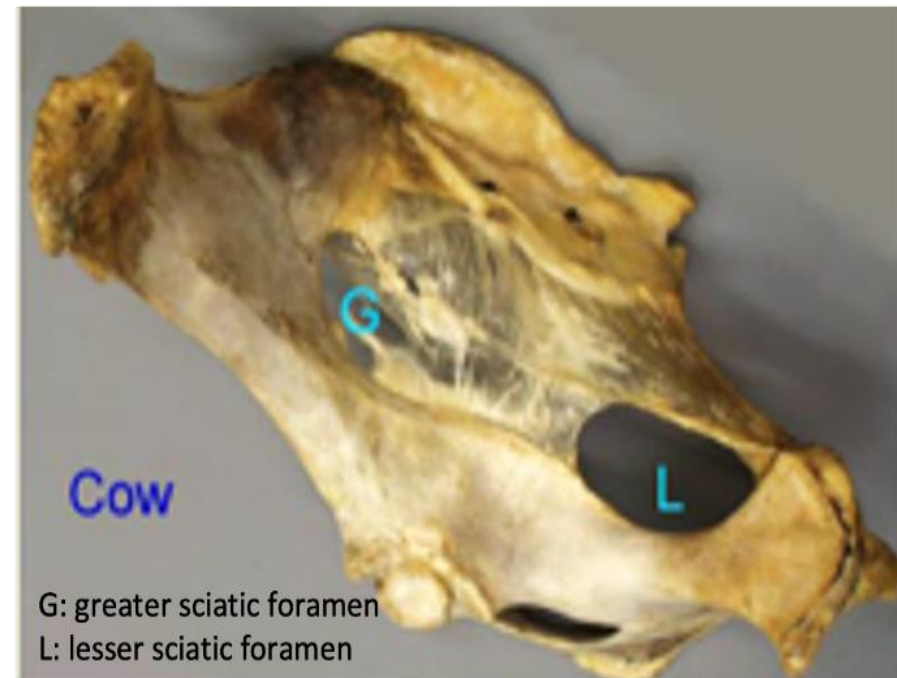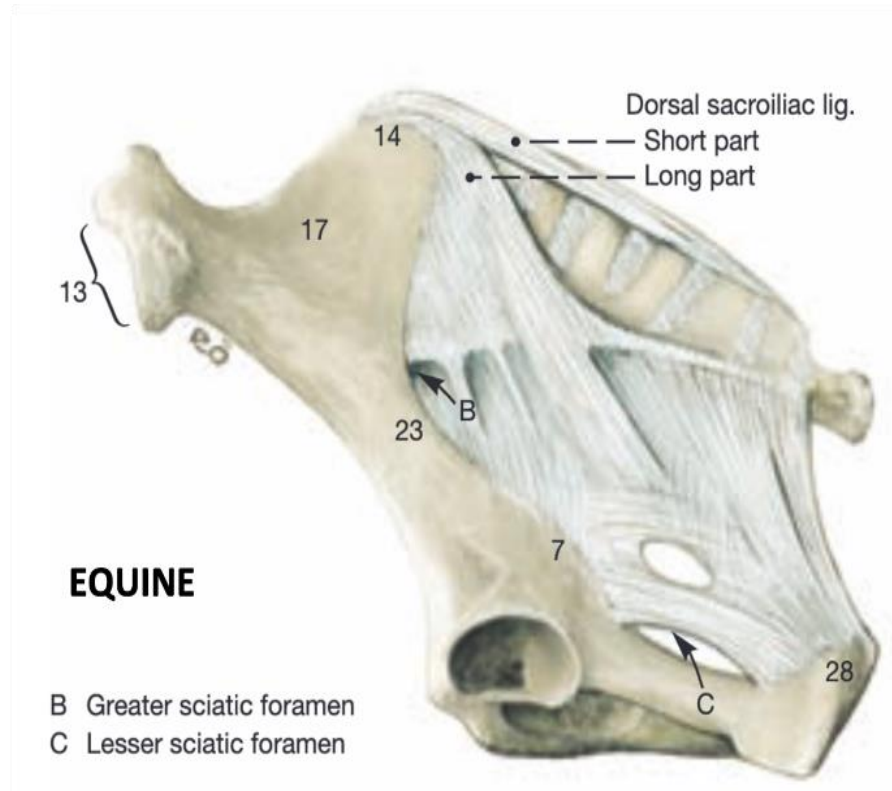
L'axe pelvien

Right lateral view of the bovine pelvis. Key: IT, tuber ischiadicum; OF, obturator foramen; P, pubis; A, acetabulum; AF, acetabular fossa; TS, tuber sacrale; TC, tuber coxae; SF, sacral foramen; black arrows, lesser ischiatic notch; black arrowheads, ischiatic spine; blue arrowheads, greater ischiatic notch.

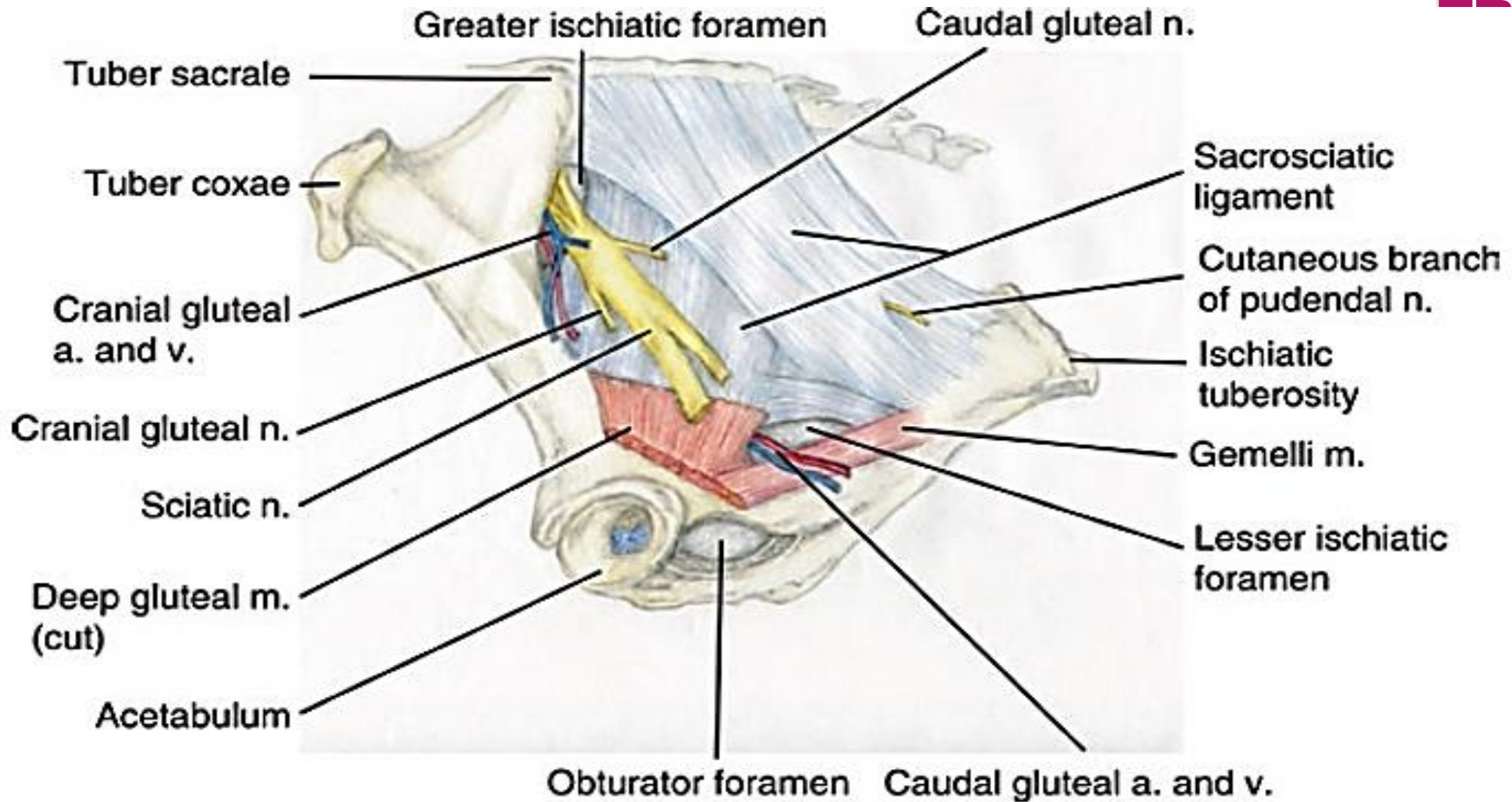


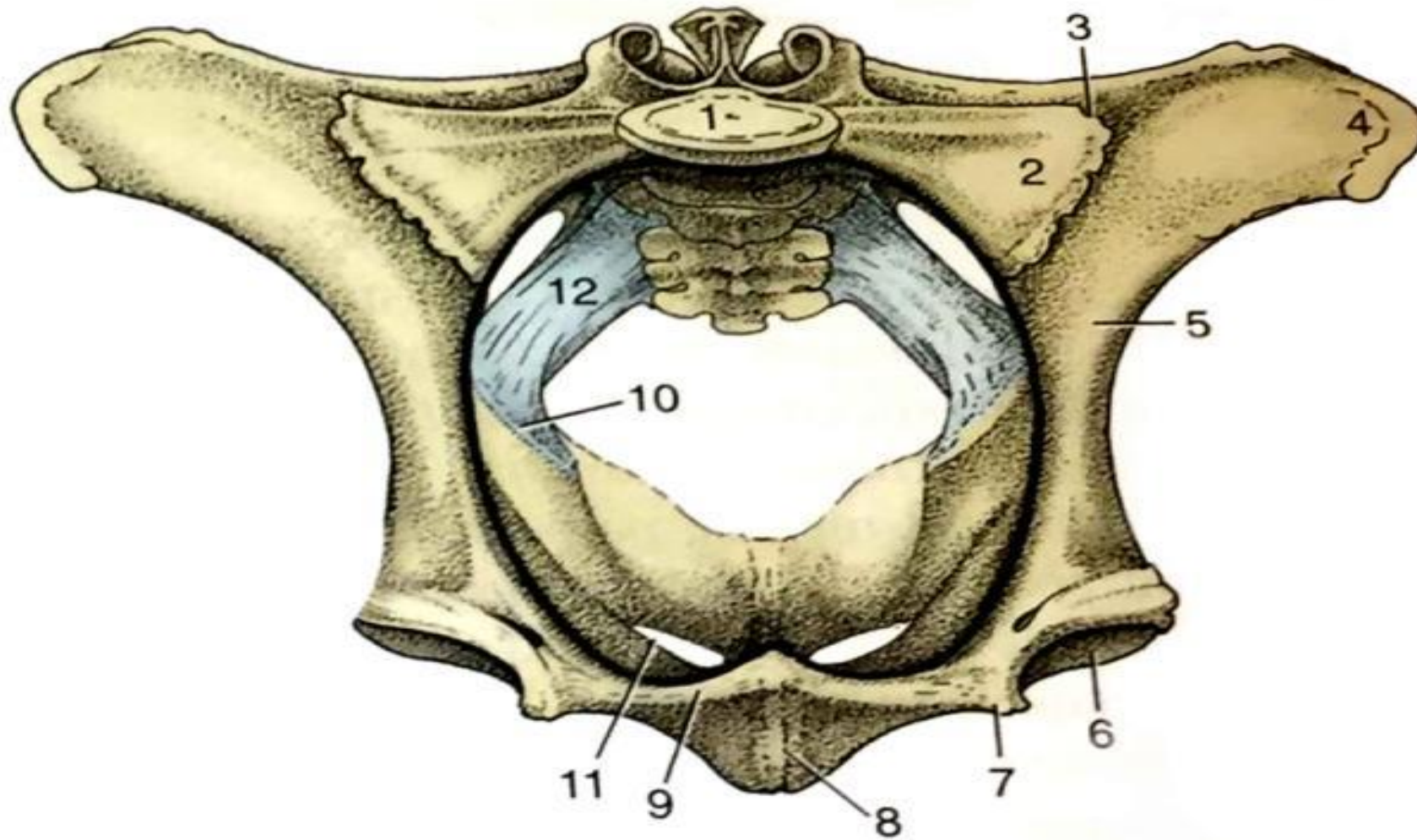


Ligaments du canal pelvien



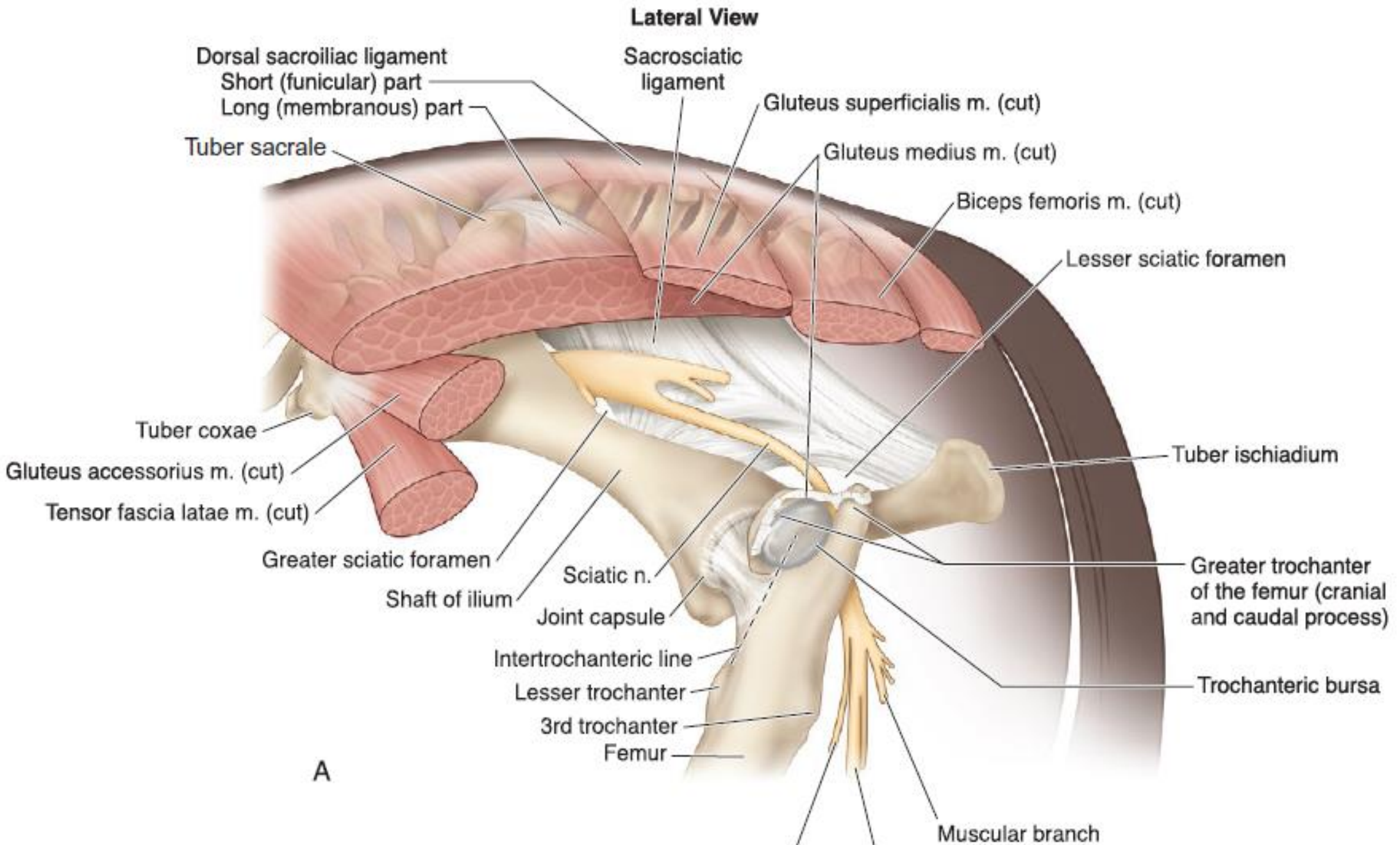
Equine (left) and bovine (right) lateral view of pelvic bone and sacrosacral ligament. Labeled structures: B or G, greater sciatic foramen; C or L, lesser sciatic foramen.

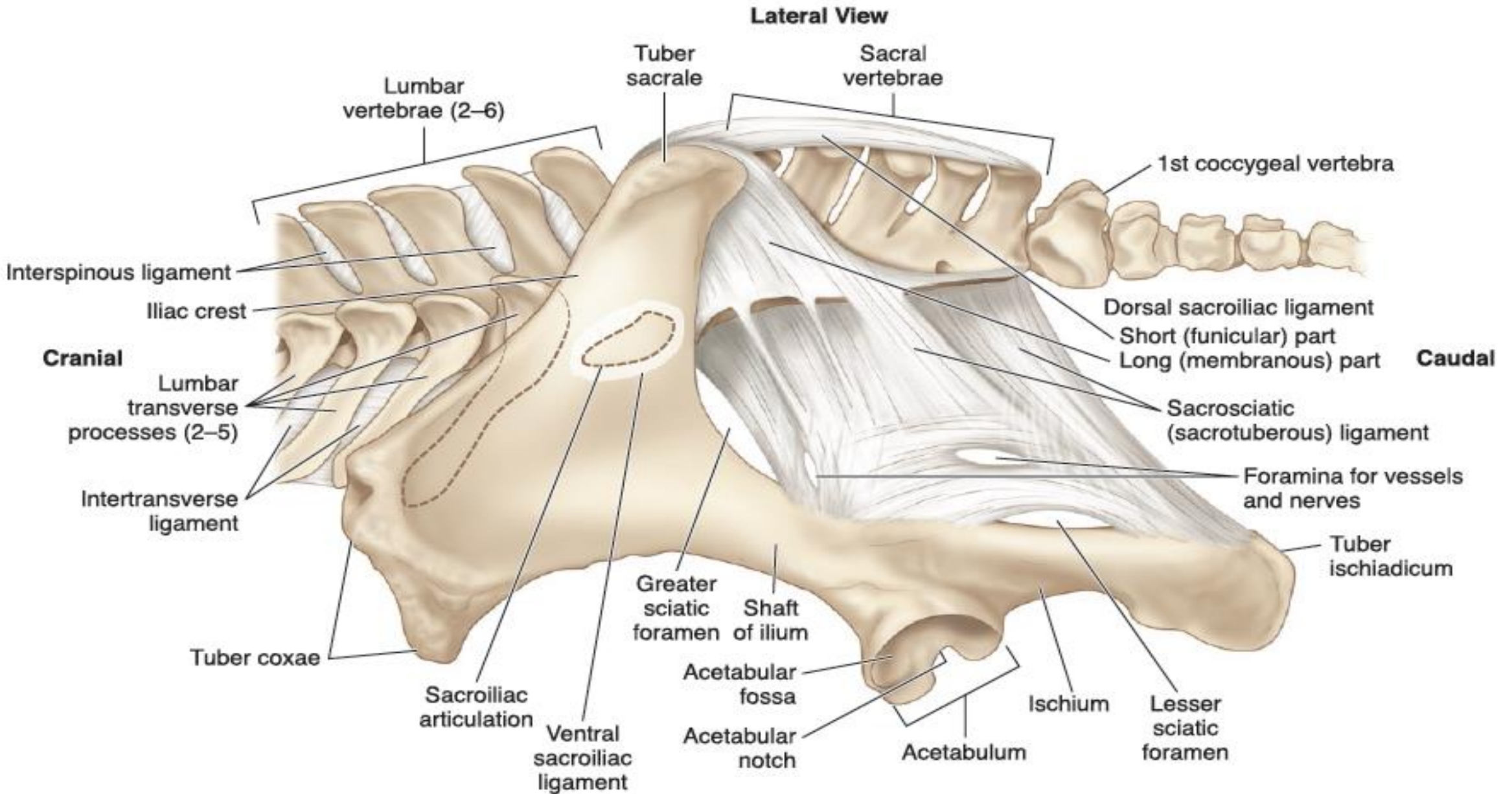




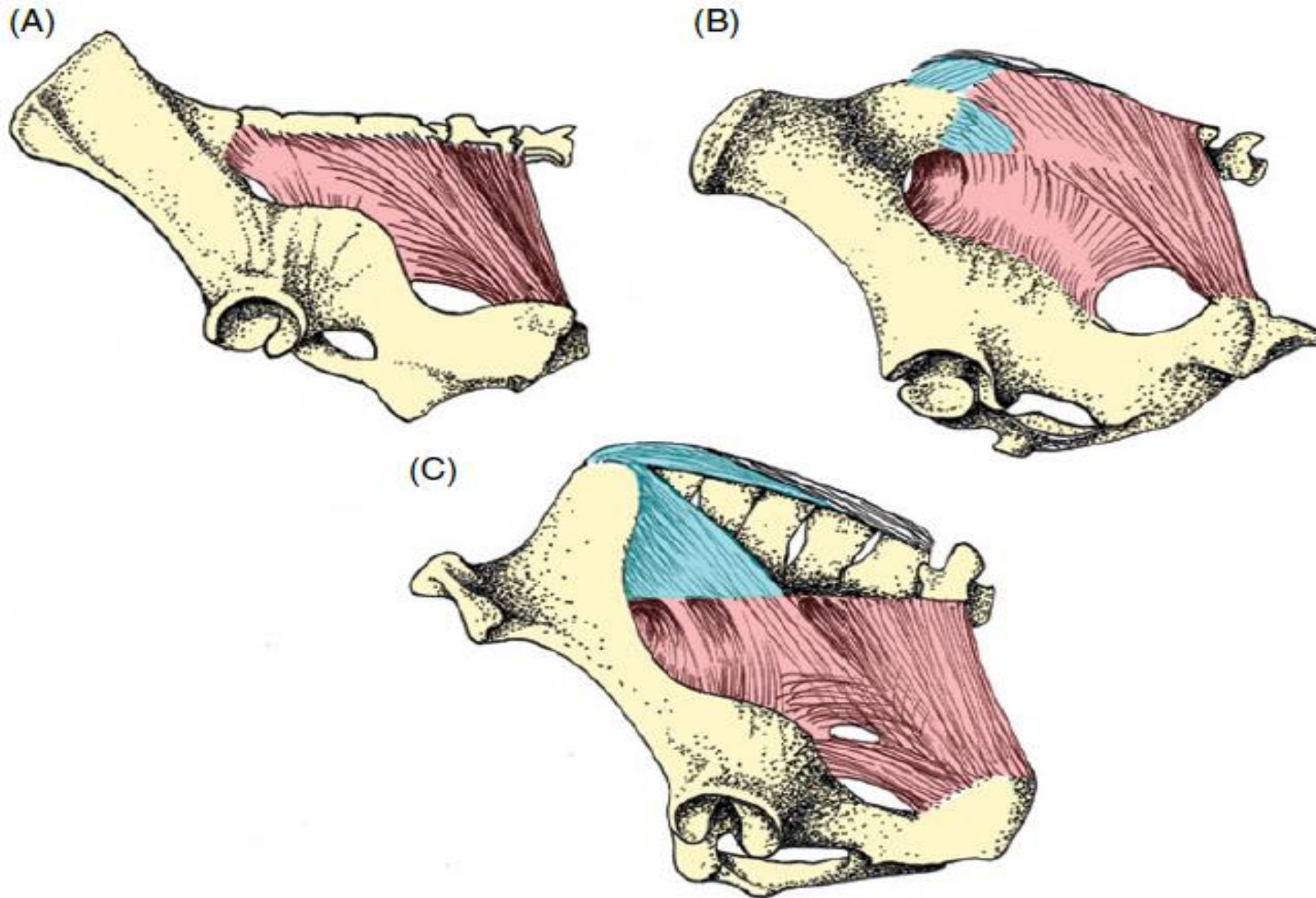
Localisation du ligament sacro-sciatique dans le bassin en vue crâniale
(Dyce, Sack et Wensing, 2009).

1-1^{ère} vertèbre sacrale, 2- Aile du sacrum, 3- Articulation sacro-iliaque, 4- Epine iliaque ventro-crâniale, 6- Acetabulum, 7- Eminence iliopubienne, 8- Symphyse, 9- Tubercule pubien, 10- Epine sciatique, 11- Foramen obturé, 12- Ligament sacro-sciatique





Lumbar, sacral, and coccygeal vertebrae, hemipelvis, and ligaments comprising the equine pelvic cingulum (girdle).



Ligaments of the pelvis, left lateral view. Sacrotuberous ligament red, dorsal iliosacral ligaments blue.
(A) Porcine. (B) Bovine. (C) Equine.

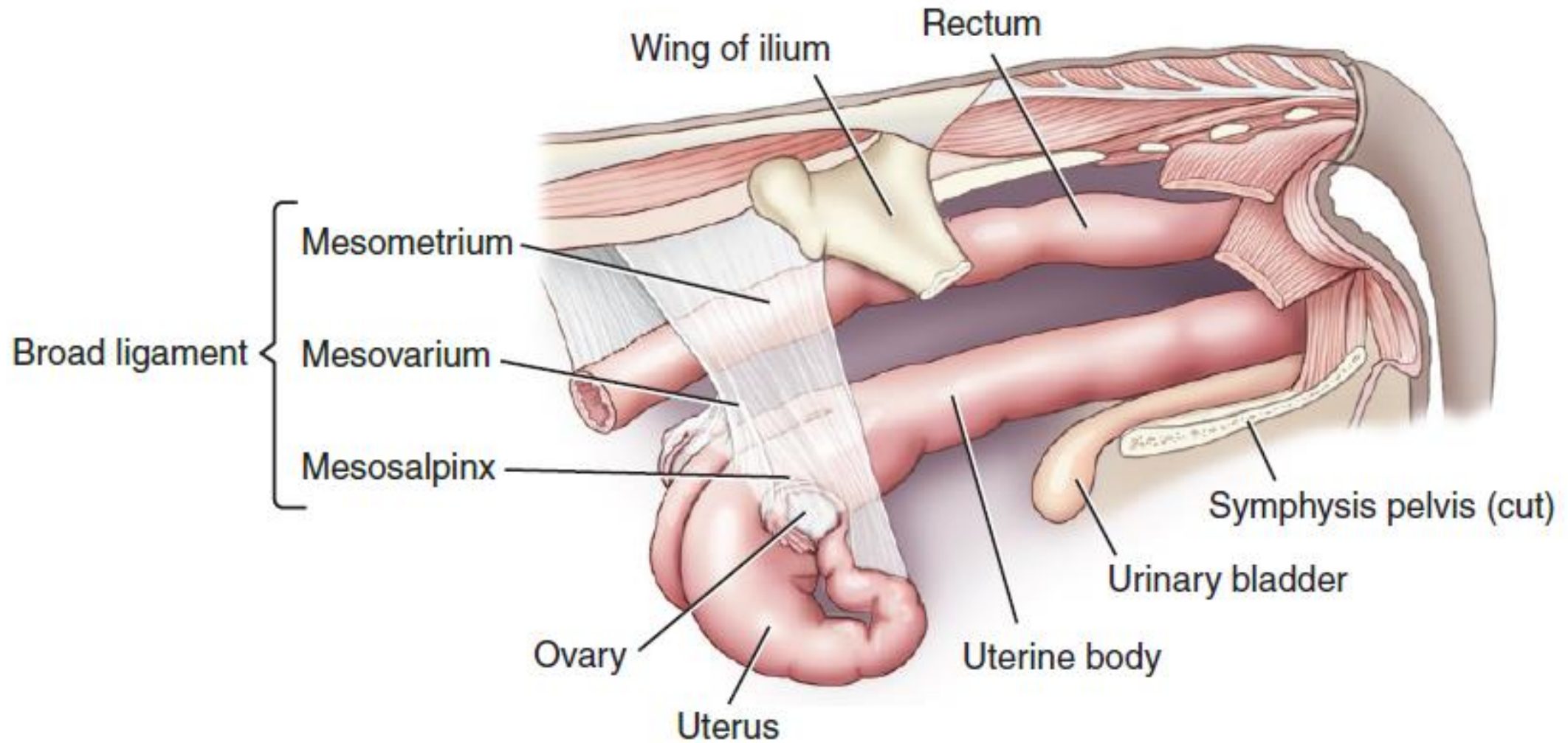
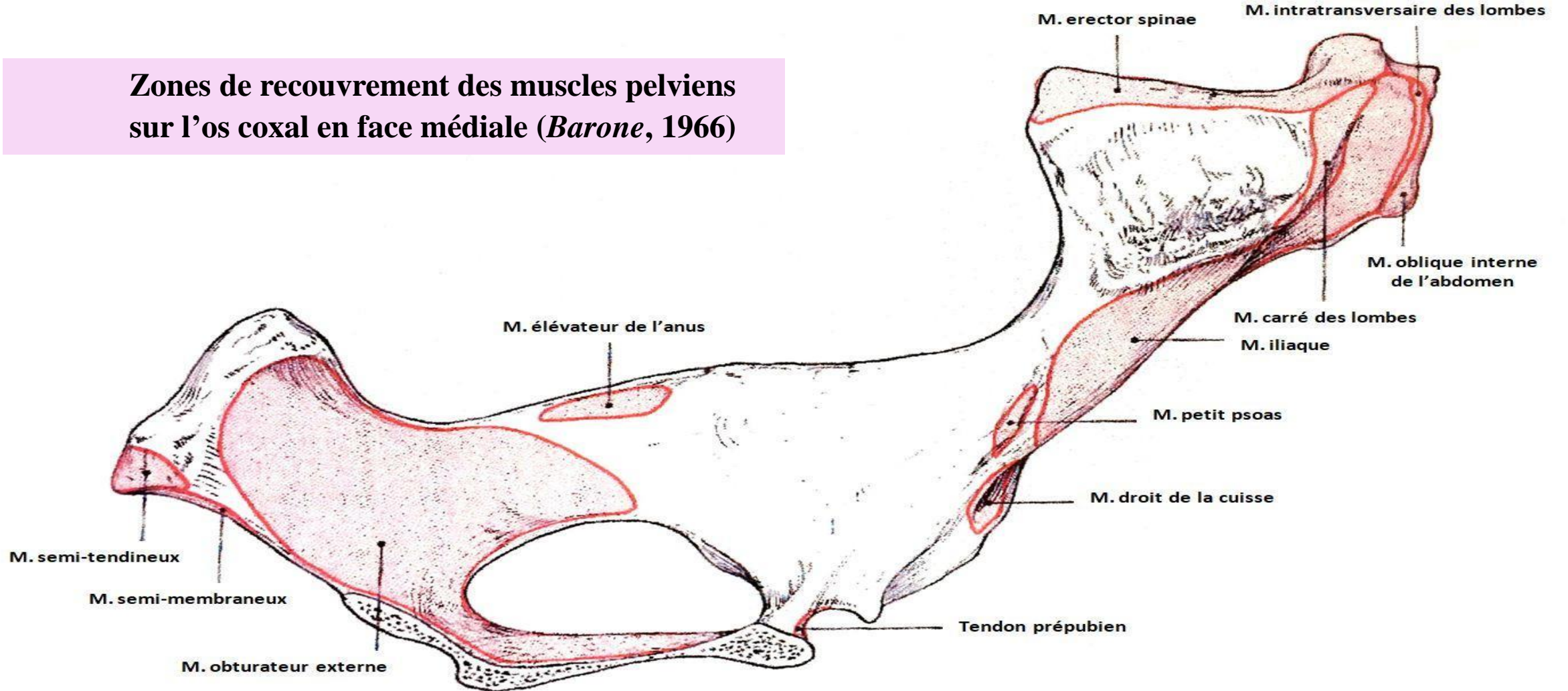


FIGURE 20.2-10 Broad ligament of the cow. The broad ligament is formed from the confluence of the mesometrium, the mesovarium, and the mesosalpinx.

LES MUSCLES PELVIENS

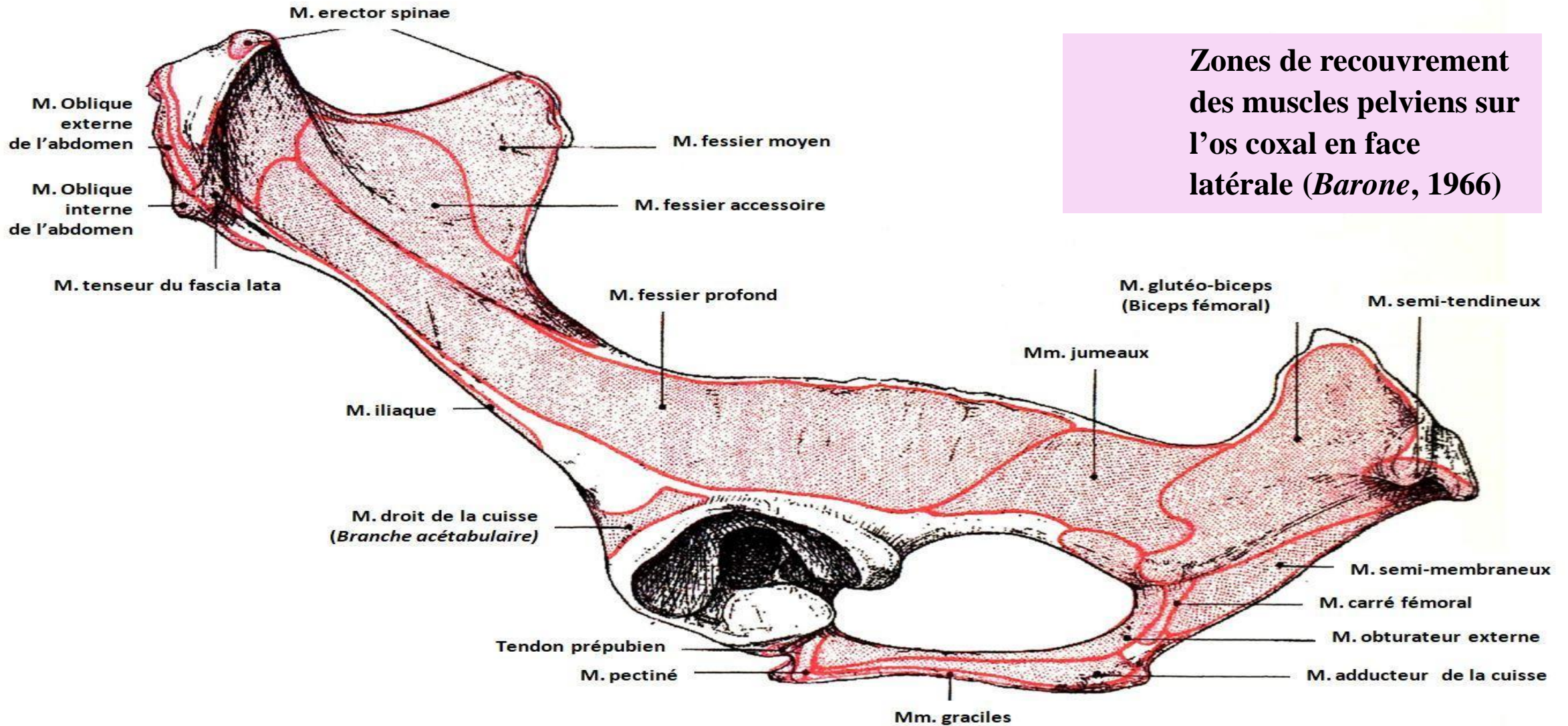
19

Zones de recouvrement des muscles pelviens sur l'os coxal en face médiale (*Barone, 1966*)

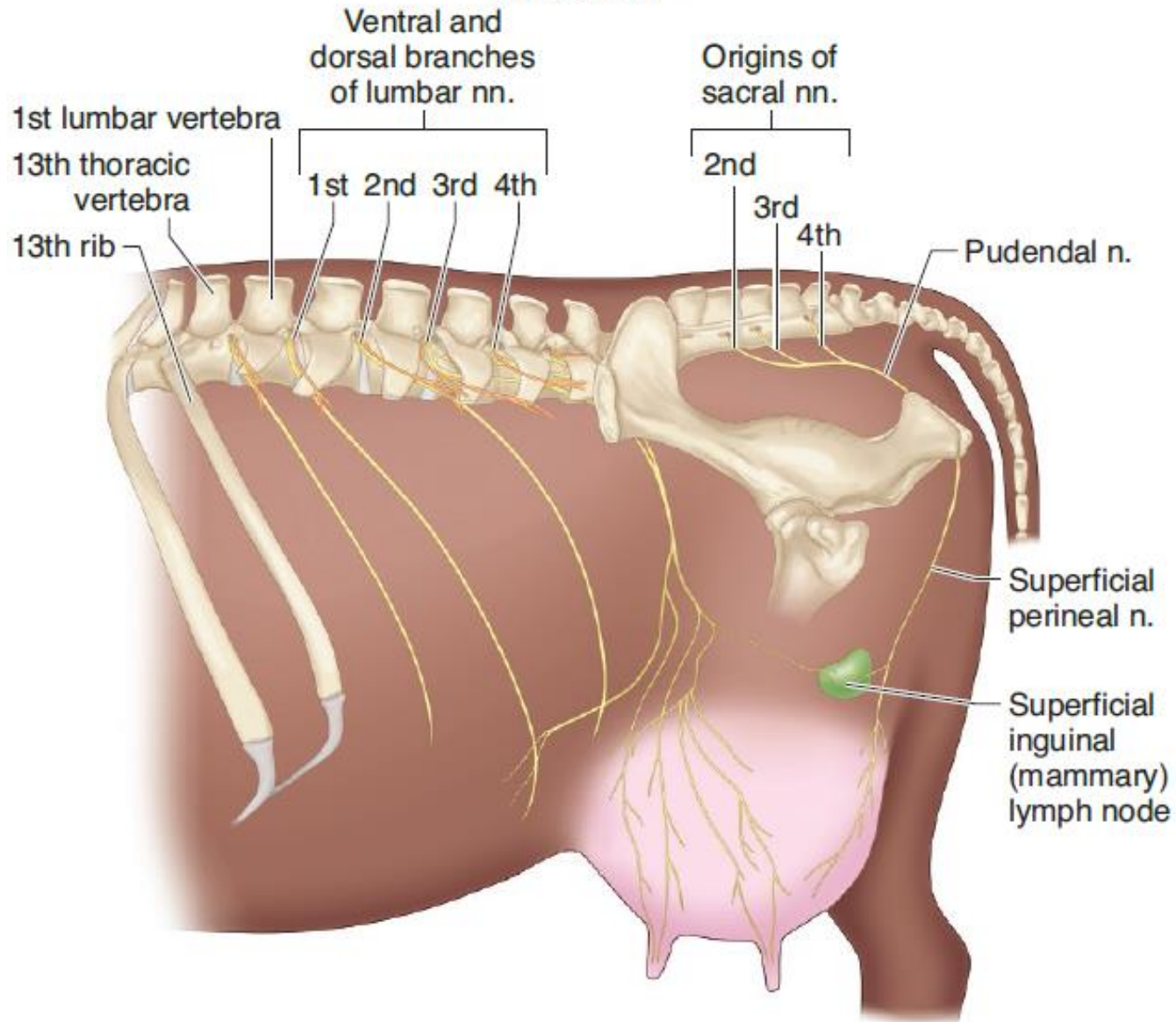


LES MUSCLES PELVIENS

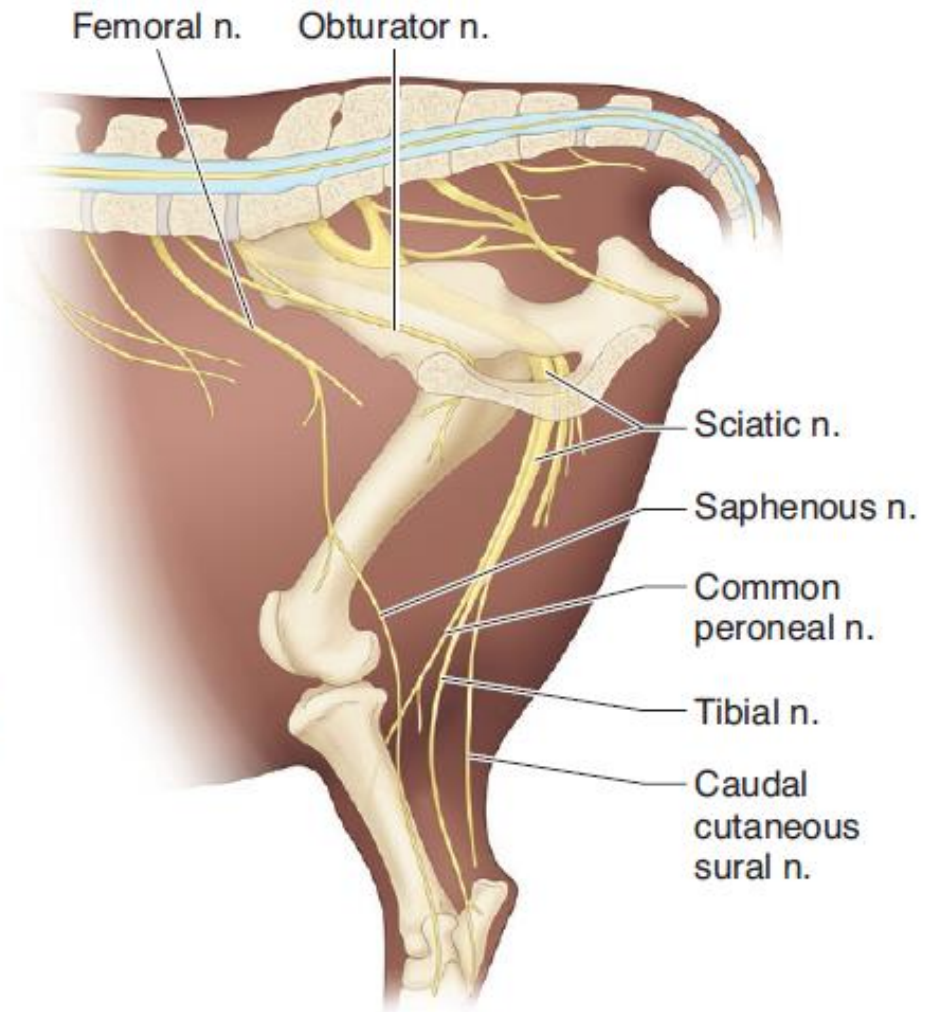
20

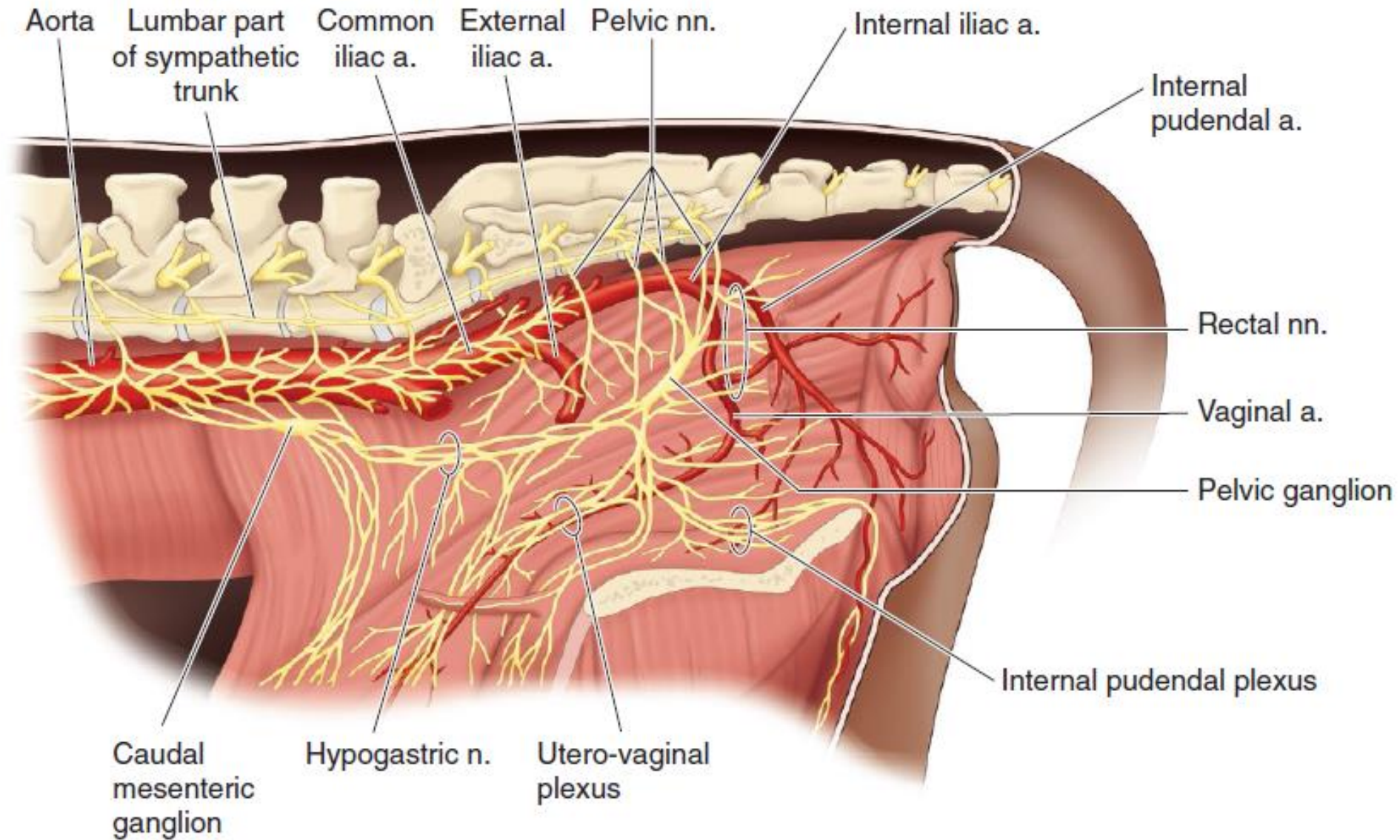


Lateral View

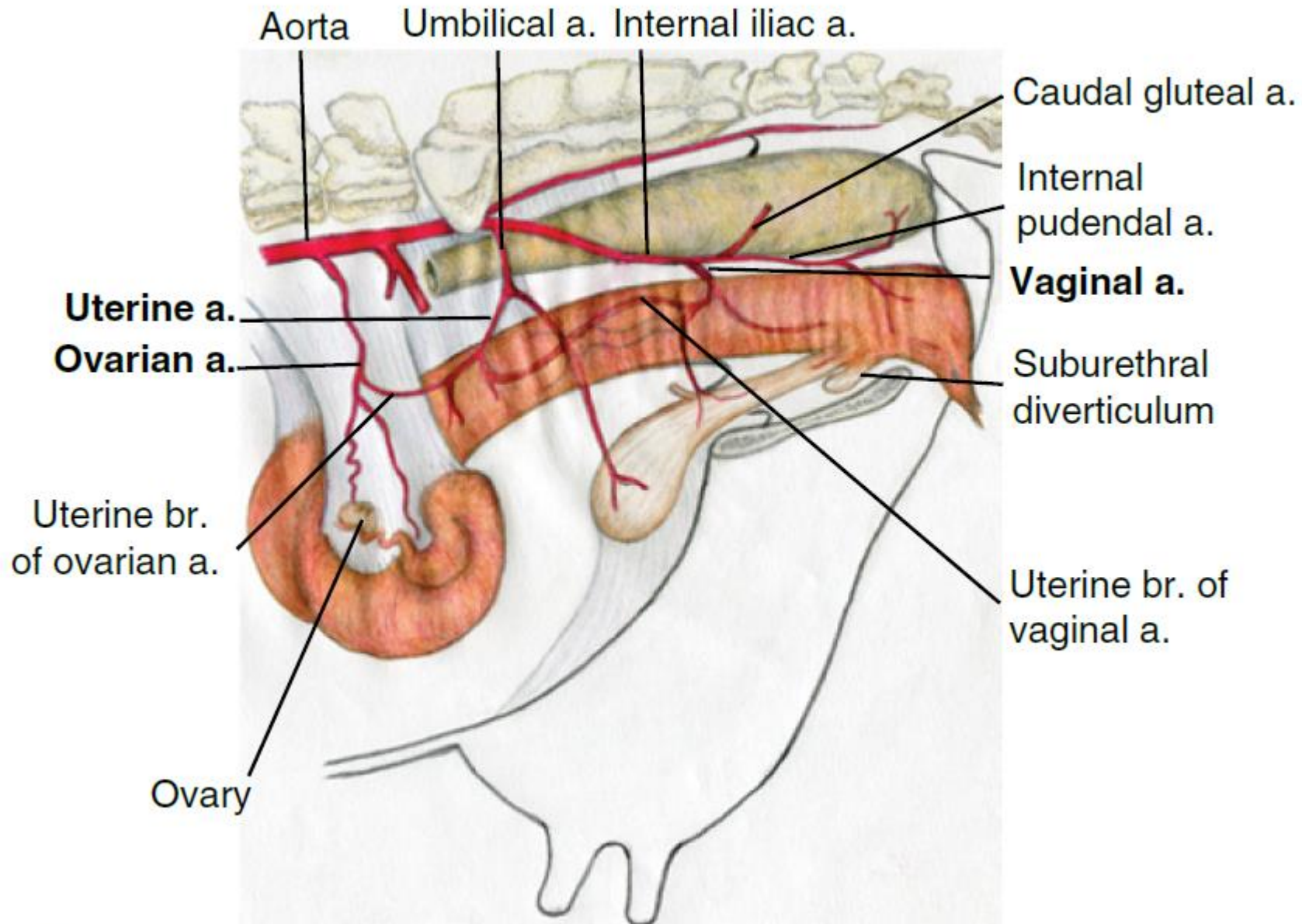


Medial View

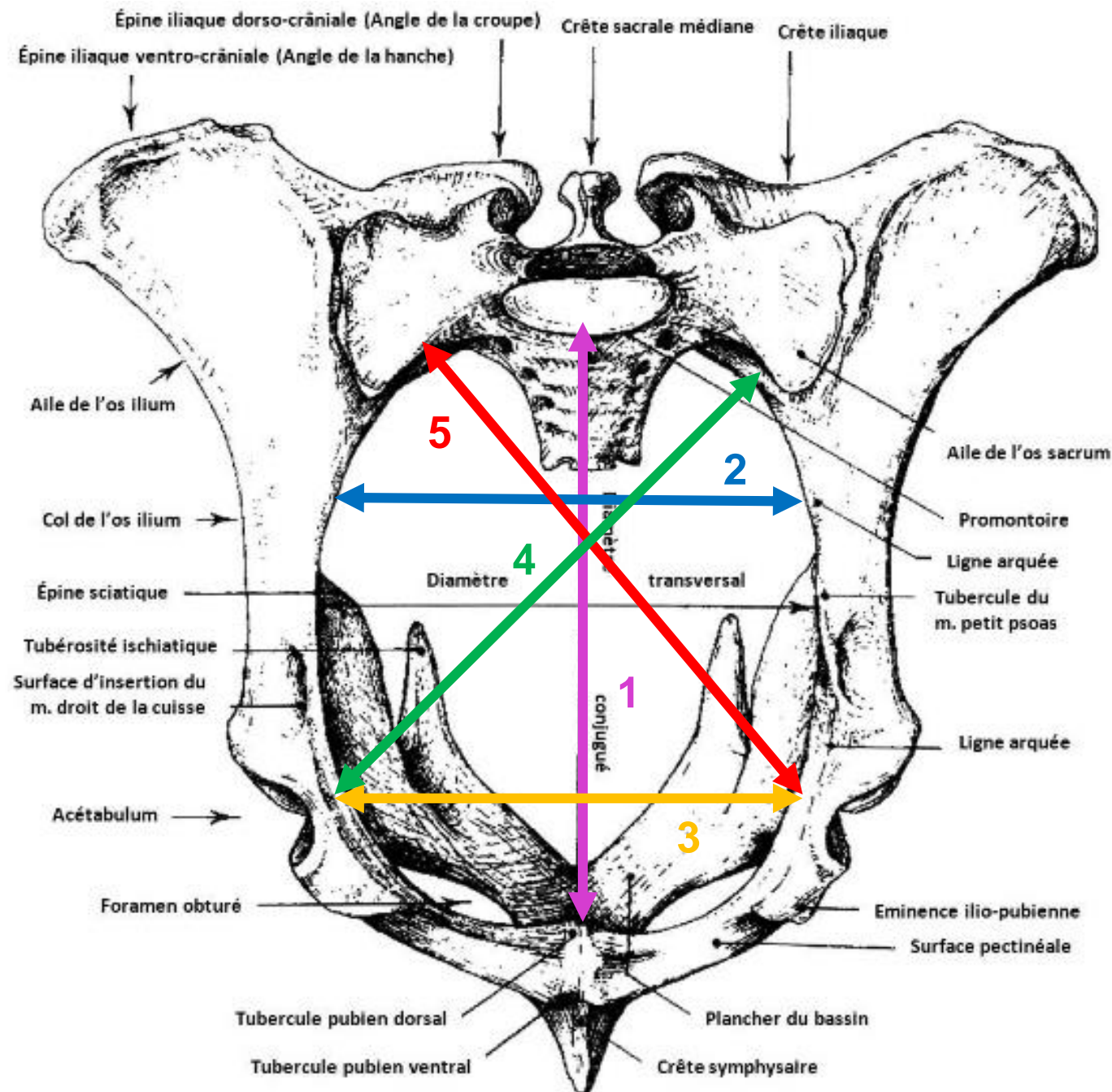




Blood supply and innervation to the bovine perineal area.



In situ schematic illustration of arterial blood supply to the bovine (cow) reproductive tract.

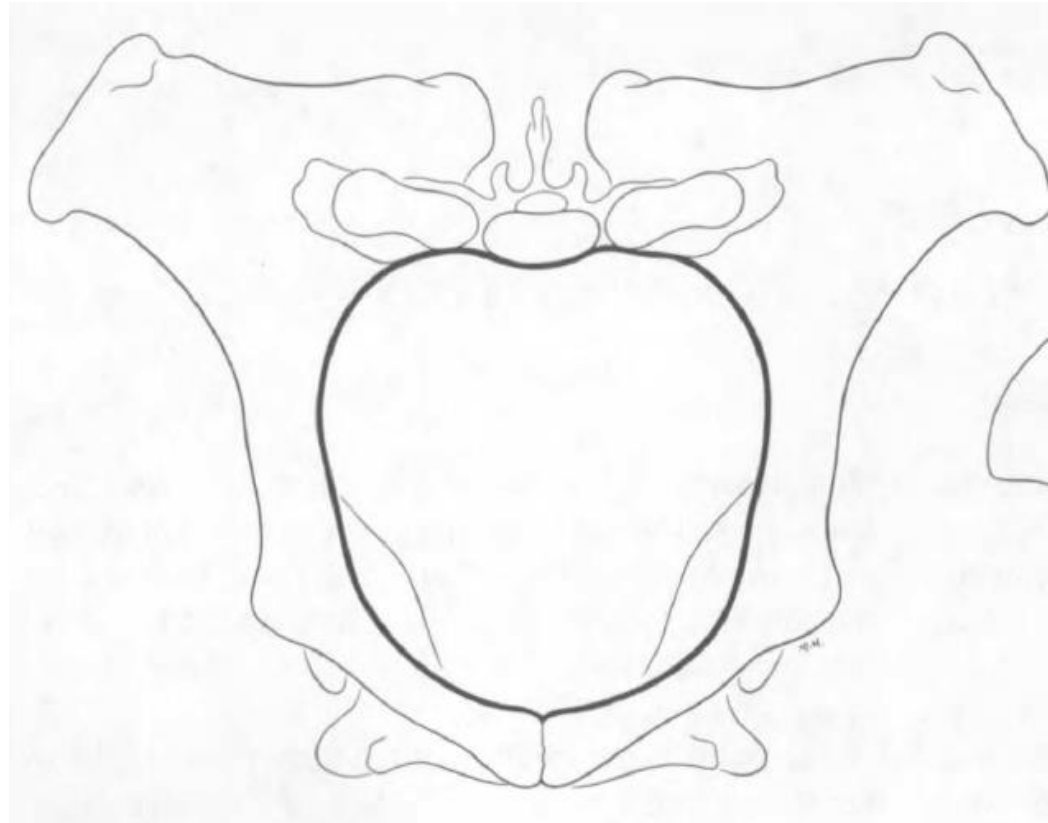


Détroit antérieur du bassin de la vache

- 1 : Diamètre sacro-pubien
- 2 : Diamètre bisiliaque supérieur
- 3 : Diamètre bisiliaque inférieur
- 4 : Diamètre sacro-iliaque droit
- 5 : Diamètre sacro-iliaque gauche

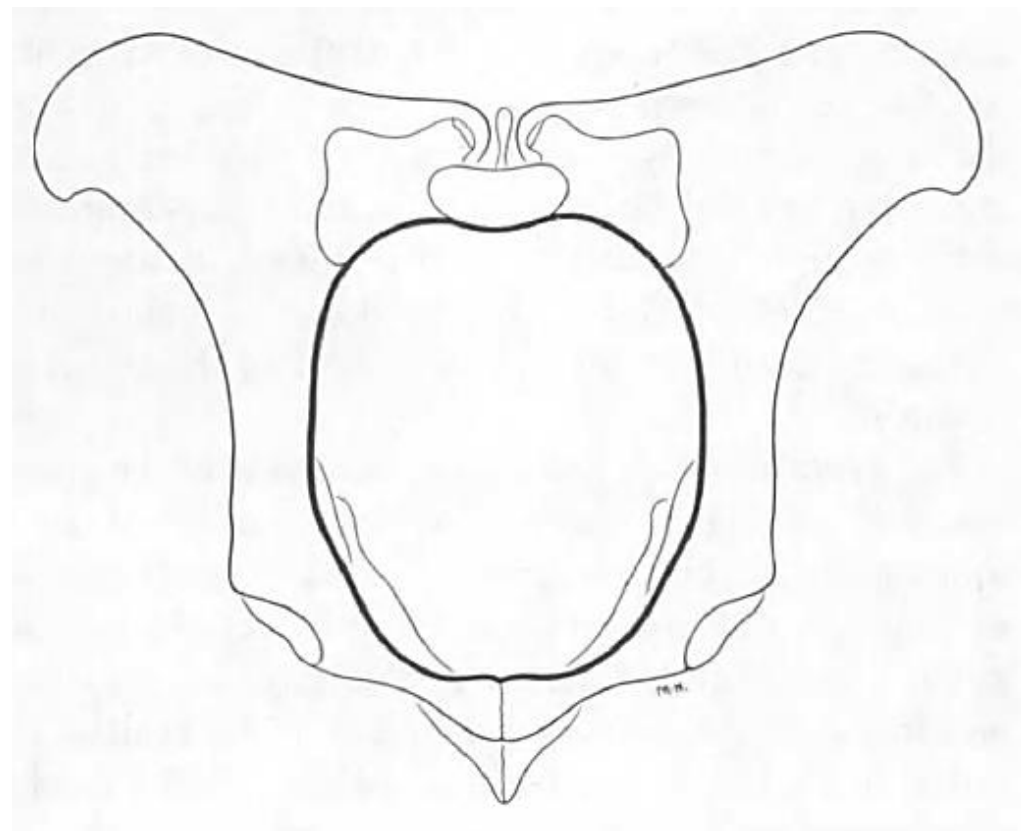
Vue crâniale d'un bassin osseux de vache
 (Barone, 1966)

Caractéristiques du bassin de la jument



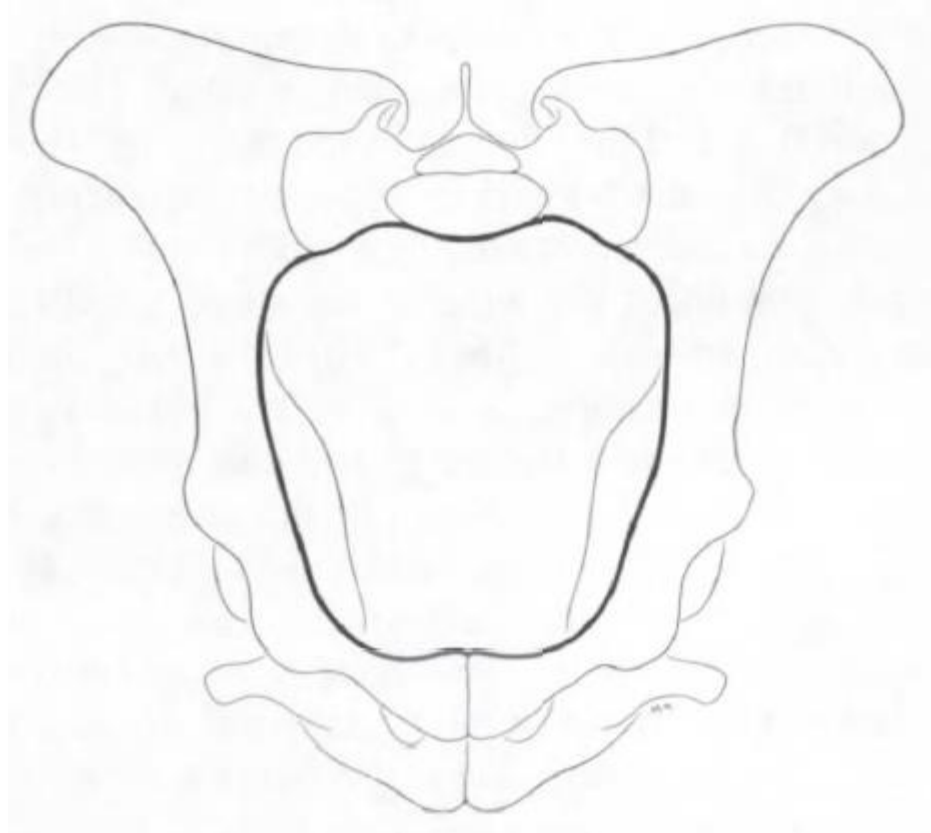
Bassin de la jument

Caractéristiques du bassin de la vache



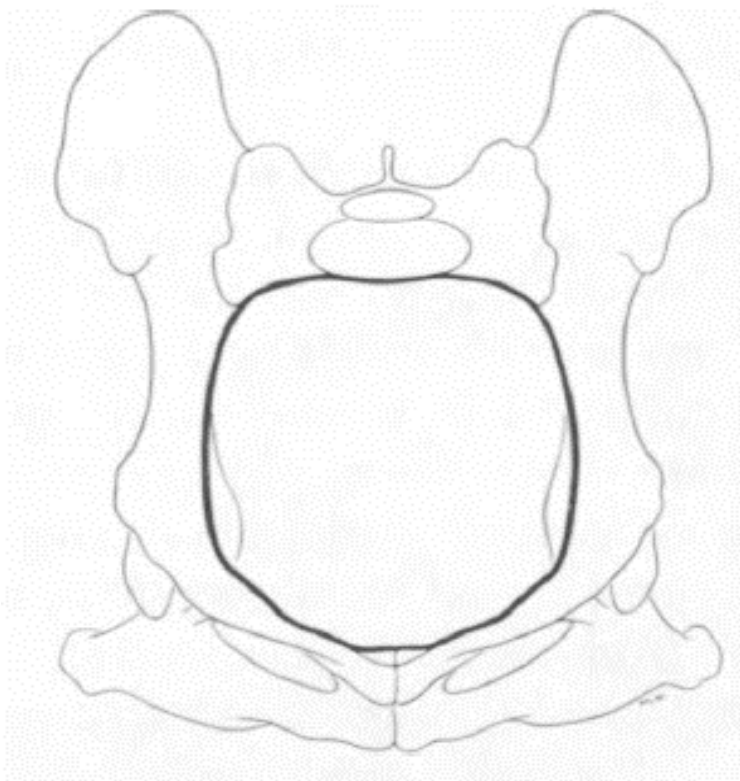
Bassin de la vache

Caractéristiques du bassin des petits ruminants

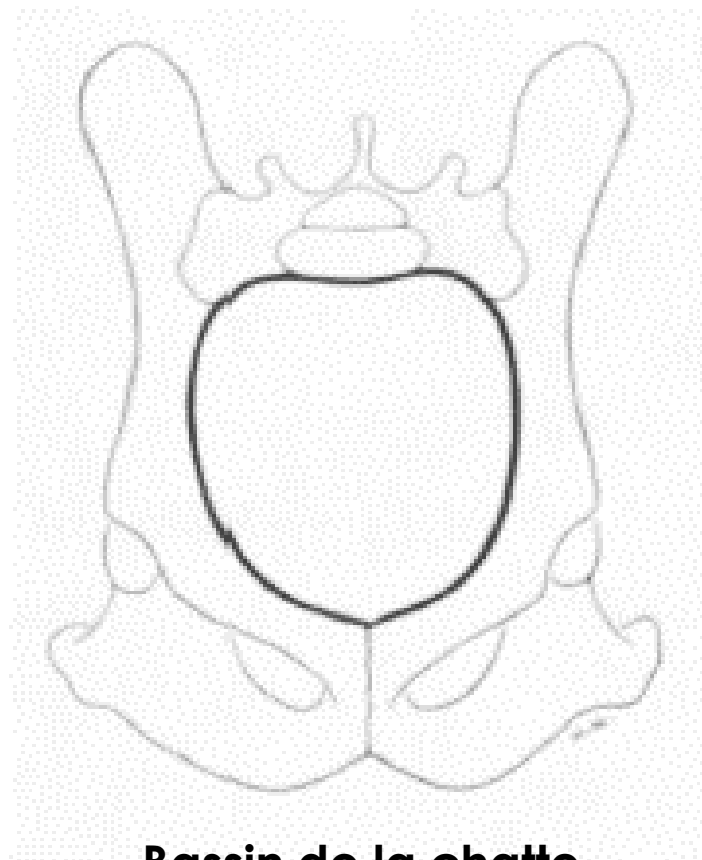


Bassin de la brebis

Caractéristiques du bassin des carnivores



Bassin de la chienne



Bassin de la chatte